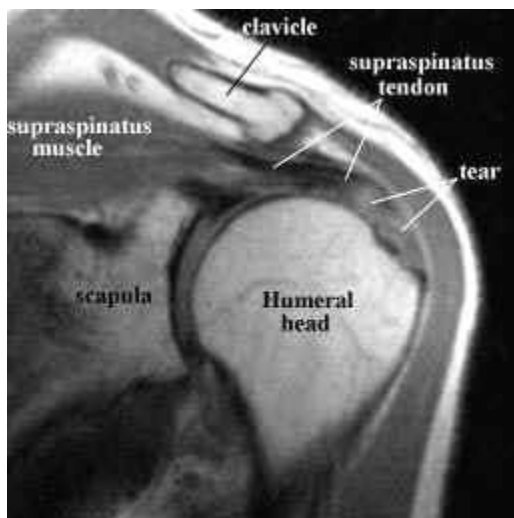


Posted by: John R. Schultz M.D. Tags: [alternatives to rotator cuff surgery](#), [stem cell therapy for rotator cuff tears](#), [supraspinatus rotator cuff tear](#) Posted date: October 13, 2010 | Comment

The rotator cuff is comprised of 4 principles muscles and their tendons: supraspinatus, infraspinatus, subscapularis and teres minor. Collectively they stabilize the joint and allow for movement . Tendons at the end of the rotator cuff muscles can become torn resulting in pain and restriction in motion. The majority of tears occur in the supraspinatus tendon. Typical presentation includes pain with impaired motion. Surgical treatment often involves arthoscopic repair, subacromial decompression or use of an anchor to secure the tendon to the bone. Surgical complications included fatty atrophy, re-tears of the rotator cuff, infection and failure.

JG is a 32y/o patient at the [Centeno-Schultz Clinic](#) who suffered shoulder injury after a motor vehicle accident. Despite surgery in the form of subacromial decompression JG continued to have shoulder pain. Repeat MRI demonstrated near complete rotator cuff tear involving the supraspinatus. He declined surgery and opted to undergo the [Regenexx procedure](#) whereby he could use his own [mesenchymal stem cells](#).



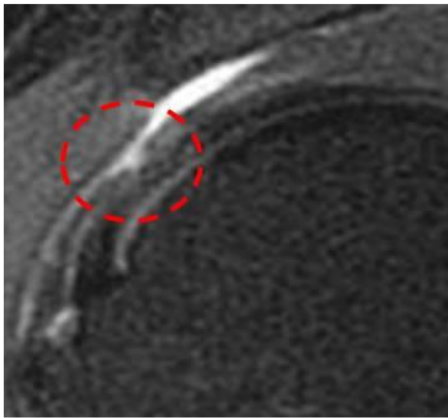
2 years after stem cell therapy JG reports greater than 90 % reduction in pain and full range of motion. Post stem cell injection MRI is posted below. The supraspinatus tendon is outlined with red circle. On the left there is a significant tear whereas on the right the tear is significantly improved. This corresponds with JG's clinical improvement. Other patients have also undergone [successful stem cell therapy for rotator tendon tears](#).

# Supraspinatus Tear: Stem Cell Therapy

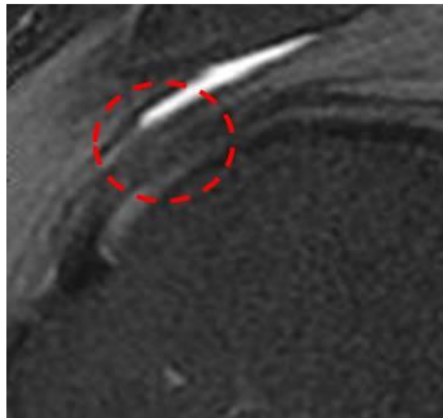
## JG:Stem Cell Injection 11.30.2007

MRI: Pre-Injection 9.13.2007

MRI: Post Injection 1.16.2009



MRI: COR T2 PD FS ET=7, TR=2750,  
TE=49.2



MRI: COR: T2 PD FS ET=7, TR=2916,  
TE=54

### Comment for Repair of Rotator Cuff Tear with Stem Cells

***stemcelldoc***

Chris,

I am pleased that you are able to see the improvement in the images. Success rates vary from patient to patient and we are still analyzing the data from all the patients we have treated to date. In general patients who have mild to moderate tears with no evidence of retractions in a single rotator cuff tendon do quite well as judged by reduction in pain and improvement in range of motion.